

FURTHER OBSERVATIONS ON METACESTODIOSIS IN BLACK BENGAL GOAT IN BANGLADESH

M A Alim ^a, M K Islam ^a, M M Rahman ^b, M A H N A Khan ^c and M M H Mondal ^{a*}

^aDepartment of Parasitology, Bangladesh Agricultural University, Mymensingh-2202, Bangladesh

^bDepartment of Surgery and Obstetrics, Bangladesh Agricultural University, Mymensingh-2202, Bangladesh

^cDepartment of Pathology, Bangladesh Agricultural University, Mymensingh-2202, Bangladesh

(Received 19 October 2000; accepted 29 May 2001)

Examination of 430 slaughtered Black Bengal goats, 198 male and 232 female, between 1 to 2.5 years of age, revealed 210 (48.84%) *Cysticercus tenuicollis*, 31 (7.21%) *Coenurus cerebralis* and 5 (1.16%) mixed infection with *C. tenuicollis* and *C. cerebralis*, while none of the goats had hydatid infection. The rate of infection was significantly ($p < 0.05$) higher in female goats than in males. *C. tenuicollis* cysts were recovered from the peritoneum and mesentery. In case of cerebral coenurosis the *C. cerebralis* cysts were found in the right and left cerebral haemispheres and median fissure of the brain. Besides from brain, coenurus cysts were also isolated from the diaphragm, subcutaneous tissues, the muscles of the abdomen, intercostal, thigh and neck muscles. No marked pathological changes was observed due to *C. tenuicollis*. In case of cerebral coenurosis skull bone was thin and soft. Marked tissue reaction was observed in the muscular tissues infected with coenurus cysts. There was haemorrhages, necrosis and granulomatous reactions.

Key words : Metacestodiosis, Black Bengal goat, Prevalence, Pathology.

Introduction

Quite a reasonable number of publications signify the importance of metacestodiosis in goats in Bangladesh (Ahmed and Ali 1972; Ahmed and Haque 1975; Islam 1980; Karim *et al* 1982; Hossain 1991; Islam *et al* 1995; Nooruddin *et al* 1996). However, most of the publications are on the incidence of only one type of metacestode, the *Coenurus* except the work on larval taeniids by Karim *et al* (1982) and metacestodes infection by Islam *et al* (1995). Detailed observation on the metacestode infection in Black Bengal goats in relation to their prevalence, organ involvement and pathological changes are scanty. An attempt was therefore made to investigate the prevalence, distribution in the body and pathological effect of metacestodiosis in Black Bengal goats.

Materials and Methods

The Black Bengal goats slaughtered at the Cooperative Market, Bangladesh Agricultural University Campus, Mymensingh, Bangladesh from November, 1996 to October, 1997 constituted the material in this study. A total of 430 (198 male and 232 female) animals were examined. The age of the animals ranged from 1-2.5 years as determined by examining the teeth. To detect the presence of metacestode, the carcasses were opened accordingly and the various organs were examined carefully. The cranial cavities were opened and the

brain tissues were examined for the presence of *C. cerebralis* cysts. The cysts were identified following the description of Soulsby (1982). The length of *C. tenuicollis* and diameter of *C. cerebralis* were measured by calipers after removing the external coating of the cysts. A large number of heads resembling the scolices were counted in the inner surface of the *C. cerebralis* cysts. All the affected organs were examined carefully to note the gross changes. The representative muscular tissues were taken, and preserved in 10% neutral buffered formalin solution. They were processed, sectioned and stained with haematoxylin and eosin stain for pathological study according to the standard procedure (Luna 1968). Statistical analysis was done by Chi-square (X^2) test (Gupta 1983).

Results and Discussion

Prevalence. Out of 430 goats examined, 210 (48.84%) were found infected with *C. tenuicollis* and 31 (7.21%) with *C. cerebralis*. Mixed infection with *C. tenuicollis* and *C. cerebralis* was found in 5 (1.16%) goats, while none of the goats had hydatid cysts. Among the sex group the prevalence of metacestodes infection was significantly ($p < 0.05$) higher in female than in male (Table 1). The *C. tenuicollis* cysts were detected more in the peritoneum than in the mesentery and the coenurus cysts were found more frequently in the tissues other than the brain. In the brain tissues the cysts were found mainly in the left cerebral hemisphere than in the right one and the median fissure. In the other organs

*Author for correspondence
E-mail : vetbau@mymensingh.net

they were isolated mainly from thigh, diaphragm, subcutaneous tissues, shoulder, intercostal and abdominal muscles and less frequently in the masseter and neck muscles (Table 2). As many as 7 cysts (2 coenurus and 5 *C. tenuicollis*) were recovered from a goat. The length of *C. tenuicollis* was 1.9 cm (5.8 ± 0.53) and the diameter of *C. cerebralis* cyst was 2-15 (4.82 ± 0.70). A well developed coenurus cyst was recovered from the intercostal muscle of a 2.5 years old male goat (Fig 1). The number of scolices recorded from each coenurus cyst was 158-803 (306 ± 37.14).

The prevalence of *C. tenuicollis* recorded in this study is in close conformity with Karim *et al* (1982) but much lower than the findings of Islam *et al* (1995). The rate of coenurosis recorded is in agreement with Ahmed and Ali (1972) and Islam

Table 1

Prevalence of metacestodiosis in black bengal goat

Sex	No. Examined	No. Infected (%) with various types of metacestodes			
		<i>Cysticercus tenuicollis</i>	Coenurus cysts	Hydatid cysts	Mixed
Male	198	87 (43.94)	9 (4.55)	-	1 (0.51)
Female	232	123 (53.02)*	22 (9.48)*	-	4 (1.72)
Total	430	210 (48.84)	31 (7.21)	-	5 (1.16)

* Indicates the significantly ($p < 0.05$) higher rate of infection than the rest in the same column.

Table 2

Organ distribution of metacestodiosis in black bengal goat

Name	Parameters Category	Types of metacestodes	
		<i>Coenurus</i> Animals infected (%)	<i>C. tenuicollis</i> Animals infected (%)
Peritoneum	-	-	180 (85.71)
Mesentery	-	-	30 (14.29)
Brain	Left cerebral haemisphere	7 (22.28)	-
	Right cerebral haemisphere	4 (12.90)	-
	Median fissure	-	1 (3.23)
Subcutaneous tissues	-	-	3 (9.68)
Diaphragm	-	-	3 (9.68)
Muscles	Thigh 5	(16.13)	-
	Intercostal	2 (6.45)	-
	Abdominal	2 (6.45)	-
	Shoulder	2 (6.45)	-
	Masseter	1 (3.23)	-
	Neck	1 (3.23)	-

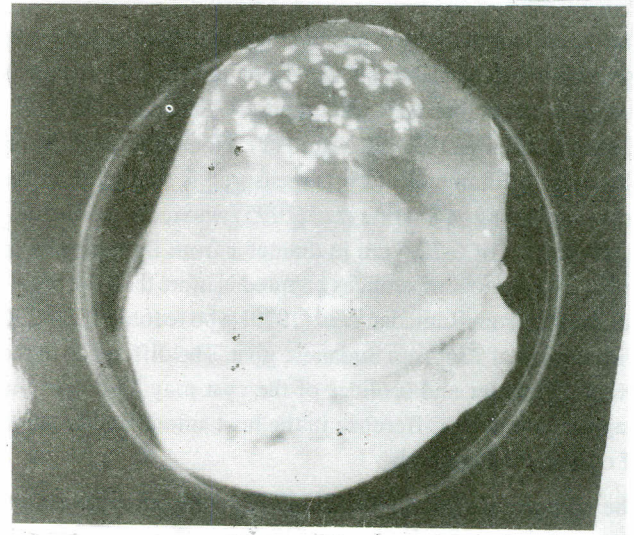


Fig 1. A mature coenurus cyst recovered from the intercostal muscle of goat.

et al (1995). This finding is slightly higher than the previous finding of Hossain (1991) and much higher than the report of Karim *et al* (1982), however, lower than the earlier report of Sanyal and Singh (1983) in goats of West Bengal, India. The variation of the findings might be due to the difference in the place of study, grazing management, age of the goats and the sample size. The higher rate of infection in female than in male is substantiated with the earlier report (Esch 1967) in mice and jackrabbits infection with larval stage of *Taenia multiceps*. The significant ($p < 0.05$) difference in the prevalence of infection is in contrast to the previous reports (Karim *et al* 1982; Hossain 1991; Islam *et al* 1995). The causes of higher prevalence of infection in females are difficult to explain, but it might be due to the hormonal (oestrogen and progesterone) influence, pregnancy and lactation as has been postulated by Esch (1967). Moreover, the females are usually grazed in the open pasture and they are voracious eater. On the other hand, the males are normally stall fed and less allowed to graze in the open pasture. Possibly the causes mentioned above make the females to get more chance to have the infection.

The isolation of coenurus cyst from the muscle and subcutaneous tissues is in agreement with the earlier studies (Soulsby 1982; Jubb *et al* 1993; Sharma *et al* 1995; Nooruddin *et al* 1996). The presence of *Taenia gaigeri* metacestodes in the intramuscular tissues (Ramadan *et al* 1973; Karim *et al* 1982) was not observed in the present study. *T. gaigeri* is regarded synonymous with *T. multiceps* (Soulsby 1982; Reiwecke 1983). *T. multiceps* metacestodes may reach maturity intramuscularly and subcutaneously other than the brain tissues of goats (Soulsby 1982). Black Bengal goats may be a suitable host to develop *T. multiceps* metacestodes other than the brain tissue.

The mean length of the cysticerci measured in this study is in agreement with Soulsby (1982). The diameter of *C. cerebralis* is slightly larger than the earlier reports (Ahmed and Ali 1972; Ahmed and Haque 1975; Hossain 1991; Nooruddin et al 1996). The range of diameter of cysts measured is smaller than the previous finding of Sharma et al (1995) who recovered subcutaneous cysts of 6-20.5 cm in diameter from Barbari goat in India. The number of scolices counted is more than the previous finding from Ramadan et al (1973) who recorded 180-296 with a mean of 236 from Sudanese goat. The difference in the length, diameter and scolices of the cyst may be due to the stage of infection, difference in the host animal and location of cyst in the host body.

The absence of hydatid infection is in contrast to the earlier reports (Islam 1980; Karim et al 1982; Islam et al 1995). It is difficult to explain the causes of absence of infection with hydatid cysts. But the age factor may play an important role. The prevalence of hydatid cyst varies with the age of the intermediate hosts and is more frequent in older animals than in the youngs (Moumen 1981; Pandey et al 1988). Moreover, in comparison with other metacestodes hydatid cysts develop slowly over several months (Soulsby 1982). Except for the major festivals, the goats of tender ages are slaughtered in the markets in Bangladesh and they do not have more time and opportunities to become infected and harbour the hydatid cysts. In addition, goats show a significantly lower rate of hydatid infection than other animals (Kamhawi et al 1995) which can be attributed to the feeding habit of goats (Rausch 1995). The ingestion of eggs of heterologous parasites such as *Taenia hydatigena*, *Taenia ovis*, *Taenia pisiformis* or *Taenia serialis* may play an important role in preventing *Echinococcus granulosus* infection in human (Rickard and Coman 1977). This immune phenomenon may also be true for goats. The ingestion of eggs and the early development of the metacestodes of *T. hydatigena* and *T. multiceps* may induce some protective mechanism against the development of the hydatid cyst.

Pathological effects. *Cysticercus tenuicollis* cysts were found in the peritoneum and mesentery. Petechial and echimotic haemorrhagic spots were evident at the site of attachment and pressure atrophy to the surrounding tissues. In the cerebral coenurosis the bone of skull at the affected site was thin, soft and in two cases there were complete absence of the bony tissues. The cysts in the brain were found mainly in the two cerebral haemispheres and median fissures with haemorrhagic spots, congestion and oedema. In the muscles, there was pressure atrophy of the surrounding tissues and development of diffuse fibrous tissues in the cystic areas. Petechial to echimotic haemorrhages were also prominent.

Greenish coloured necrotic tissues and sloughing off muscles were found in the cystic areas.

Histologically, the muscles of the affected areas were severely affected where degeneration to granuloma formation was found. The granulomatous reaction was characterized by deposition of profuse mononuclear phagocytic cells with plenty of haemorrhages (Fig 2). The muscle fibers around the granulomatous areas were degenerated, necrosed and in most of the places dissolved. There was presence of histocytes and lymphocytic infiltration in the granulomatous areas but the polymorphonuclear cells were absent. The granuloma formation was multifocal, but the remnants of parasitic cysts were not common in all places. There was deposition of oedematous fluid and the interfibrillar and interbundular spaces of the affected muscles were dilated. Fibrous connective tissue proliferation was present around the granulomatous tissues.

The pathological changes in the body of the host varied greatly with the type of cyst, organ involved and the size and fluid content of the cysts. The pathological changes caused by *C. tenuicollis* is in agreement with the earlier report of Islam et al (1995). This finding is in contrast to Sweatman and Plummer (1957), who reported fibrotic changes of the liver including adhesions of the organ in the abdominal cavity. Haemorrhagic and fibrotic tracts and viable caseated or calcified cysticerci (Soulsby 1982) were also not observed. This variation may be due to the organ involved, stage of infection and the host response to the infection. The pathological changes in the brain tissues strengthen the earlier reports (Parihar 1988; Islam et al 1995). The presence of haemorrhages, necrotic and fibrous tissue can be explained by the degenera-

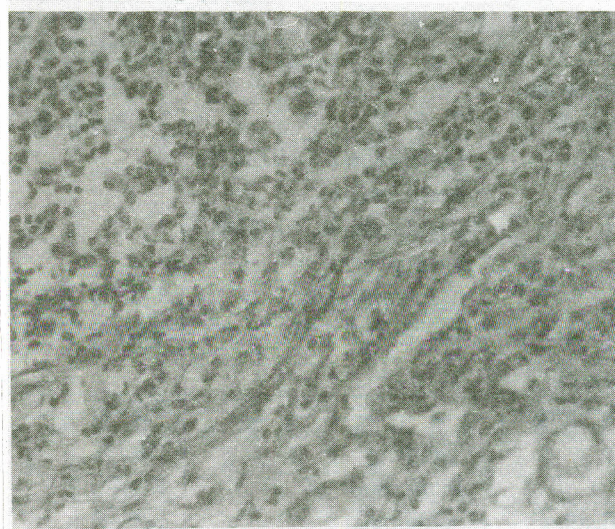


Fig 2. Granulomatous myositis showing extensive muscular damage with profound infiltration and accumulation of macrophages, lymphocytes and eosinophils (400 X, H & E).

tion and destruction of blood vessels, normal muscle structures and host responses to the infection.

The presence of granulomatous reaction indicates the chronic condition of the infection. The infiltration of lymphocytes and mononuclear phagocytic cells in the granulomatous area is in agreement with the earlier findings of Larsh *et al* (1965). However, there was no infiltration of polymorphs and both foreign body and Langerhan's type giant cells (Larsh *et al* 1965). The muscle degeneration, necrosis and dissolution are in agreement with Singh and Singh (1972) who described necrosis and complete loss of normal structure in *T. multiceps* affected goat. Calcification, infiltration of polymorphs and extensive fibrosis (Singh and Singh 1972) were not observed. The variation in the finding might be the organ involved and stage of infection. The presence of congestion, oedema and haemorrhages strengthened the earlier reports (Soulsby 1982; Islam *et al* 1995).

The observations on metacestodiosis that have been described in this paper may not reflect the exact pictures in Black Bengal goats in Bangladesh. The real infection rates are likely higher since the present figures are derived from the slaughtered goats where mostly the young and apparently healthy goats are sacrificed.

References

- Ahmed J U, Haque M A 1975 Surgical treatment of coenurosis in goats, *Bangladesh Vet J* **9** 31-34.
- Ahmed S, Ali M I 1972 Incidence of *Coenurus cerebralis* in goats in Bangladesh. *Indian Vet J* **49** 1157-1158.
- Esch G M 1967 Some effects of cortisone and sex on the biology of coenuriasis in laboratory mice and jackrabbits, *Parasitol* **57** 175-179.
- Gupta S P 1983 *Statistical Methods*. Sultan Chand and Sons Publ., 23 Darvaganj, New Delhi 110002, India, 19th ed.
- Hossain M A 1991 Incidence of gid disease in goats, *Bangladesh Veterinarian* **8** 14-17.
- Islam A W M S 1980 Hydatid disease in goats in Bangladesh. *Vet Parasitol* **7** 103-107.
- Islam M K, Mondal M M H, Das P M 1995 Metacestodes infection in Black Bengal goats in Bangladesh, *Asian-Australasian J Anim Sci* **8** 13-16.
- Jubb K V W, Kennedy C P, Palmer N 1993 *Pathology of Domestic Animals*. Aca. Press. Inc. Harcourt Brace Jovanovich Publ., San Diego, New York, Boston, 4th ed pp 290.
- Kamhawi S, Hajjawi N, Abu-Ghazaleh A, Abbas M 1995 Prevalence of hydatid cysts in livestock from five regions of Jordan, *Ann Trop Med Hyg* **89** 621-629.
- Karim M J, Shaikh H, Huq M M 1982 Prevalence of larval taeniids in Bangladesh. *Trop Anim Hlth Prod* **14** 166.
- Larsh Jr J E, Race J R, Gerold W E 1965 A histologic study of mice infected with the larval stage of *Multiceps serialis*, *J Parasitol* **51** 45-52.
- Luna L G 1968 *Manual of Histologic Staining Methods of the Armed Forces Institute of Pathology* McGraw Hill Book Company, New York 3rd ed, pp 12-46.
- Moumen A 1981 *Epidemiologie de hydatidose echinococcose dans la region de Quarzazate*. Theses Doctorate Veterinarie, IAV Hassan II, Rabat, Morocco.
- Nooruddin M, Dey A S, Ali M A 1996 Coenuriasis in Bengal goats of Bangladesh. *Small Rumin Res* **19** 77-81.
- Pandey V S, Ouhelli H, Moumen A 1988 Epidemiology of hydatidosis/echinococcosis in Quarzazate, the Pre-Saharan region of Morocco, *Ann Trop Med Parasitol* **82** 461-470.
- Parihar N S 1988 Pathology of *Coenurus cerebralis* in ovine subclinical infections. *Indian J Anim Sci* **58** 539-543.
- Ramadan R O, Magzoub M, Adam S E I 1973 Clinico-pathological effects in a Sudanese goat following massive natural infection with *Coenurus gaigeri* cysts. *Trop Anim Hlth Prod* **5** 196-199.
- Rausch R L 1995 *Life Cycle Pattern and Geographic Distribution of Echinococcus species*, eds Thomson R C A & Lymbery A J, CAB International Wallingford, UK pp 89-134.
- Reiwecke R K 1983 *Veterinary Helminthology*. Butterworth, Durban, South Africa pp 392.
- Rickard M D, Coman B J 1977 Studies on the fate of *Taenia hydatigena* and *Taenia ovis* larvae in rabbits and cross immunity with *Taenia pisiformis* larvae. *Int J Parasitol* **7** 257.
- Sanyal P K, Singh P K 1983 Caprine metacestodiasis: Incidence in West Bengal. *Haryana Veterinarian* **22** 38-40.
- Sharma D K, Sanil N K, Agnihotri M K, Singh N 1995 Subcutaneous coenuriasis in Barbari goat. *Indian Vet J* **72** 1203-1205.
- Singh K P, Singh S P 1972 Occurrence of multiceps cysts in the lymphnode of goat *Capra hircus*. *Indian Vet J* **49** 1156-1157.
- Soulsby E J L 1982 *Helminths, Arthropods and Protozoa of Domesticated Animals*. Balliere, Tindall and Cassell, London, 7th ed pp 113-123.
- Sweatman G K, Plummer P J G 1957 The biology and pathology of the tape worm *Taenia hydatigena* in domestic and wild hosts. *Canadian J Zool* **35** 93-109.